

INVESTIGATING ALLERGIC SKIN DISEASE

Allergies in horses are commonly encountered but, given their prevalence, are poorly understood, often difficult to investigate, and frustrating to treat. Serum Allergy Testing (SAT) and Intradermal Testing (IDT) are commonly used to diagnose allergic dermatitis. There is little evidence basis for the use of SAT or IDT in the diagnosis of respiratory allergies or suspected food intolerance.

In human and veterinary medicine, IDT remains the “gold-standard” for diagnosing allergic skin disease, although SAT is popular because of its convenience. In one study of three commonly used equine SATs, all tests had poor sensitivity and poor positive predictive value when compared to IDT. The best of the 3 tests had a sensitivity of only 37% and a positive predictive value of only 48.5%. In one study of horses with RAO, levels of IgE and IgA in serum were not elevated despite significant elevations in IgE and IgA in bronchoalveolar lavage fluid.

Although IDT is accepted as the gold standard in dermatology it is far from perfect. False positive results are common and in most normal horses a few false positive tests are expected. A positive skin test reaction indicates that the patient has allergen-specific IgE fixed to mast cells that causes them to degranulate. Care in interpretation and experience in reading the tests is therefore important as is thorough history taking. IDT remains the recommended technique at Liphook Equine Hospital.

TREATMENT

Based on the findings of the IDT recommendations could include exclusions from the allergen if possible or the introduction of an Allergen Specific Immunotherapy. The vaccination protocol has been shown to lead to resolution of signs and cessation of drug therapy in 59% of cases, 9% of cases had corticosteroids removed from their treatment protocol, 16% needed to stay on medications but improved and the remainder did not respond.

Further reading

Stepnik, C. T. *et al.* (2011) Equine atopic skin disease and response to allergen specific immunotherapy: a retrospective study at the University of California-Davis (1991-2008). *Veterinary Dermatology*, 23, 29-e7.



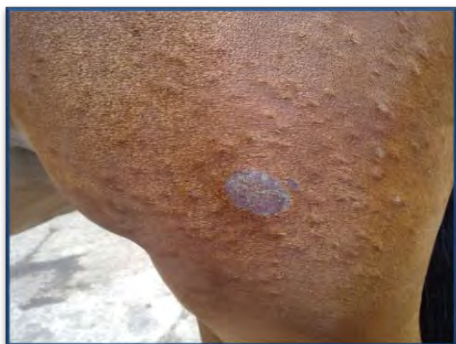DIAGNOSTIC AIDS IN THE INVESTIGATION OF EQUINE SKIN DISEASE

Empirical treatment may often be an attractive and appropriate initial approach to cases seen in first opinion practice, although it is possible that this may confuse the results of later tests. Diagnostic tests are best performed early in the course of equine skin diseases (and repeated if necessary) to confirm a definitive diagnosis and ensure specific treatment and management is provided.

SKIN SCRAPINGS are often collected and submitted from equine dermatology cases without good justification. This is a methodology primarily useful for identification of mite infestations, which are rare causes of skin disease in horses with the exception of *Chorioptes* which is best diagnosed by brushings (see later). Superficial skin scrapings are collected from the skin surface without causing bleeding and are best for *Sarcoptes sp.*, *Psoroptes sp.* (ear mites), *Chorioptes sp.* (leg mange), *Dermanyssus gallinae* (poultry mite), forage mites and harvest mites. Deeper skin scrapings from the intrafollicular space and superficial dermis should be deep enough to cause bleeding. This is primarily useful for burrowing mites (*Sarcoptes sp.* and *Demodex sp.*) and also nematode larvae such as *Pelodera spp* or *Strongyloides sp.*. Occasional *Demodex* mites on facial scrapes may be normal.

SELLOTAPE PREPARATIONS are primarily used for detection of *Oxyuris equi* eggs around the anus, vulva and perineum which may cause pruritus around the tail base. The sellotape test can also be used for detecting superficial mite infestations such as *Chorioptes* and also other avian or free living forage and hay mites. For *Oxyuris* eggs the tape should be pressed firmly in several sites in the perianal area. *Chorioptes* mites might be better detected by brushing (eg toothbrush) the surface skin scales onto the tape. *Chorioptes* mites are very mobile and the tape helps stop them running away!

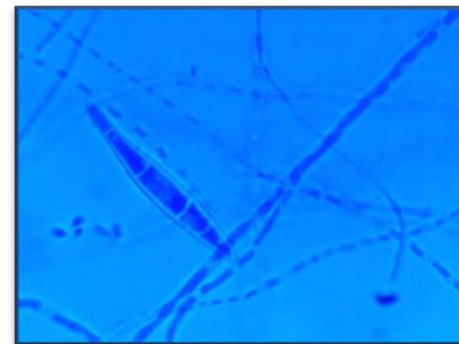
HAIR PLUCKS are indicated whenever there is hair loss, broken hairs, crusts, scales or altered growth patterns particularly if dermatophytosis (or dermatophilosis) is suspected. It is best performed with rubber-covered artery forceps **and this is a far better sample for fungal culture and microscopy than scrapes**. Dermatophyte growth is best obtained from hair plucks following alcohol spraying the skin to reduce contaminants. Microscopic examination for dermatophytosis based on plucks from the margins of the lesions offer the highest diagnostic rate. Direct microscopic identification of dermatophytes can be difficult and negative findings during direct microscopy does not rule out dermatophytosis. Definitive findings in dermatophyte infections are hyphae and arthrospores in the hair shaft but these are seen only in 50-60% of cases at most. All suspected dermatophyte samples should be further cultured to help confirmation and identification of the species (see below).



Typical papular and scaling and crusting dermatophytosis lesions



Dark red-brown reverse pigmentation of *Trichophyton equinum* growing on Sabourauds agar



Macroconidium of *Microsporium equinum* using lactophenol cotton blue stain

DIAGNOSTIC AIDS IN THE INVESTIGATION OF EQUINE SKIN DISEASE

IMPRESSION SMEARS can be performed on impression smears taken directly from fresh scabs of suspected cases of dermatophilosis. Place 1-2 drops of saline onto a slide, clip excess hair from the scab, place underside of scab onto slide and allow to macerate for a few minutes, then remove scab from slide. Allow slide to air dry, then send to the laboratory. Demonstration of gram-positive branching of filaments of parallel rows of cocci (zoospores) is diagnostic although culture on blood agar can be helpful in confirming this.

BACTERIAL CULTURE in skin disease in horses is complicated by the fact that skin is never normally a sterile site and therefore results are frequently complicated by contaminants and commensals leading to confusion as to which bacteria are relevant and which are not. It is also important to realise that primary bacterial skin disease is extremely rare in horses as virtually all cases of bacterial dermatitis will arise because of predisposing skin damage – e.g. from wetting, trauma, photosensitisation etc... Pustules can be punctured and aspirated/swabbed although these are not commonly encountered in equine skin diseases. Bacteriology taken from underneath crusts can be helpful but are also strongly subject to contamination. Skin biopsies can also be subject to culture. The commonest potential pathogens in skin cases comprise coagulase positive *Staphylococci* and beta-haemolytic *Streptococci* although both could also be contaminants/commensals. Interpretation alongside cytologic examination (preponderance of neutrophils) is helpful for establishing pathologic relevance.

TRICHOGRAPHY (Stage of hair growth) is also an occasionally useful part of hair pluck microscopy. The main two phases of the “hair cycle” are: 1) anagen where there is active growth of the hair within the hair follicle; and 2) telogen which is the resting phase where the dead hair is retained in the follicle (catagen is an intermediate phase between the two). Anagen hairs have rounded and smooth bulbs at the root that are usually pigmented and soft so the root will usually bend at 90° to the hair shaft. Telogen hairs are characterised by a uniform shaft thickness and a slightly clubbed or spear-shaped (rather than rounded) bulb. They are usually unpigmented, rough and straight. In normal horses roots will be seen with varying ratios of anagen and telogen stage hairs and this can vary at different times of year. However, it is never normal to see all hairs in a telogen phase and if this is the case then this is consistent with the diagnosis of follicular arrest (telogen defluxion).

SKIN BIOPSIES can provide useful additional information and are most valuable if performed early in the course of disease. Self inflicted trauma particularly in pruritic animals can significantly alter primary lesions into non-specific secondary inflammatory lesions which are invariably disappointing. Sample a large enough area (minimum 6mm punch biopsy). It is important not to shave, clean or scrub the lesion prior to biopsy as this may remove key superficial diagnostic features. Infiltrate only a minimum of local anaesthetic or use a ring block to minimise artefacts caused by local anaesthetic infusion.

